



Follicular bronchiolitis: a rare disease in children

Esra Toprak Kanık¹, Özge Yılmaz¹, Ahmet Türkeli¹, Şebnem Şahin², Hasan Yüksel¹

¹Division of Pediatric Allergy and Pulmonology Unit, Celal Bayar University Faculty of Medicine, Manisa, Turkey

²Department of Pediatrics, Celal Bayar University Faculty of Medicine, Manisa, Turkey

Abstract

Follicular bronchiolitis (FB) is a benign progressive lung disease. It is characterized with lymphoplasmocellular infiltration and hyperplastic follicles in the peribronchial areas in the small airways. Follicular bronchiolitis should be considered in cases where chronic cough, recurrent upper respiratory tract infections and progressive dyspnea are observed in children. The diagnosis should be supported by lung biopsy. A 8-year old female patient presented to our hospital with complaints including continuing cough and wheezing. Bilateral extensive rales and rhonchi in the lungs were heard on auscultation and lung graphy revealed reticuloglandular appearance. Bilateral extensive septal thickenings, reticulonodular appearance, patchy bronchiectasis, bronchiolectasis and peribronchial thickenings were found on high-resolution thoracal computarized tomography. A diagnosis of follicular bronchiolitis was made as a result of lung biopsy. Improvement was observed in the complaints and findings of our patient after methylprednisolone treatment. This patient was presented to emphasize rare interstitial lung diseases should also be considered in children who present with a clinical picture of chronic bronchial obstruction and do not respond to standard treatment. (Türk Ped Arş 2014; 49: 344-7)

Key words: Child, follicular bronchiolitis, interstitial lung disease

Introduction

Follicular bronchiolitis (FB) is a rare benign lymphoproliferative disease. The disease is related with a histopathological condition characterized with hyperplasia which occurs as a result of antigenic stimulation of BALT (bronchial-associated lymphoid tissue) (1). It frequently occurs secondary to nonspecific conditions including connective tissue diseases, immune deficiencies, hypersensitivity disorders and infection (2, 3). However, primary FB cases have been reported in children, though rarely (4).

The histopathology of follicular bronchiolitis is characterized with lymphocytic infiltration which is more prominent in the peribronchiolar area and which also rarely extends to the alveolar interstitium (5). Although there is lymphocytic infiltration in the bronchial epi-

thelium, excessive alveolar septal infiltration which is observed in lymphocytic interstitial pneumonia is not observed. In approximately half of the cases, neutrophilic exuda is present in the bronchial lumen (3). In addition, secondary changes including small foci of organizing pneumonia may be observed (2).

Here, an eight-year old patient with continuing complaints and pulmonary parenchymal findings despite conventional treatment who was diagnosed with primary follicular bronchiolitis and developed severe nasal polyposis in the follow-up was presented.

Case

An eight-year old female patient presented to our hospital with the complaints of cough and wheezing which continued since the age of one year. It was stated that

Address for Correspondence: Esra Toprak Kanık, Division of Pediatric Allergy and Pulmonology Unit, Celal Bayar University Faculty of Medicine, Manisa, Turkey. E-mail: toprakesra@yahoo.com

Received: 14.10.2012 **Accepted:** 16.01.2013

©Copyright 2014 by Turkish Pediatric Association - Available online at www.turkpediatricsivi.com

DOI:10.5152/tpa.2014.306

gastroesophageal reflux treatment was administered in addition to “conventional treatment” for three years when she had cough which increased at night and did not change with exercise at the age of three years, but the complaint of cough did not regress. The patient who intermittantly received inhaled steroid treatment with a diagnosis of asthma in other healthcare institutions had no familial history of atopy or asthma. On physical examination, her growth was found to be within the normal limits and bilateral extensive fine ralles, prolonged expirium and ronchi were found. Other systemic examination findings were found to be normal.

On lung graphy, interstitial appearance which was more prominent in the middle and lower areas was observed (Figure 1). Anemia, leukocytosis or leukopenia was not found in blood tests which were performed intermittently. Hepatic and renal function tests were found to be normal. She was hospitalized and systemic steroid treatment together with nebulized steroid and short-acting bronchodilatator was started. Serum immunoglobulin levels were found to be normal in the patient whose lung auscultation revealed continuing fine rales despite treatment. The sweat test was found to be 37 mmol/L and the repeated sweat test was found to be 32 mmol/L. Tuberculin skin test was found to be normal. High resolution thoracic computerized tomography (HRCT) revealed bilateral diffuse septal thickenings, reticulonodular appearance, bronchiectasis from place to place, bronchiolectasis and peribronchial thickenings (Figure 2).

The respiratory function test findings were as follows: FVC 58%, FEV₁ 59%, PEF 59%. This was compatible with restrictive pattern. Flexible fiberoptic bronchoscopy which was performed with a prediagnosis of interstitial lung disease revealed no anatomical anomaly and microscopic examination of bronchoalveolar lavage fluid was found to be normal with a CD4/CD8 ratio of 0.93. With these findings open lung biopsy was performed and pathological examination revealed peribronchial lymphoid infiltration and lymphoid follicles which were compatible with FB (Figure 3a and b).

The tests performed in terms of the pathologies observed in the etiology of follicular bronchiolitis were as follows: ANA: negative, anti-ds-DNA: negative, p-ANCA (perinuclear type anti-neutrophil cytoplasmic antibodies) and C-ANCA (cytoplasmic type anti-neutrophil cytoplasmic antibodies): negative, serum C3: 138 mg/dL(normal), C4: 8.9 mg/dL (normal), alpha-1-antit-

rypsin: 174 mg/dL (normal), HIV (human immunodeficiency virus) serology (antiHIV): negative. With these results a diagnosis of primary FB was made and it was planned to start methylprednisolone with a dose of 1.5 mg/kg/day for 15 days and subsequently 1 mg/kg/day for 15 days with gradual tapering of the dose. In the follow-up, the symptoms and clinical findings of the patient regressed. Respiratory function tests performed after the 6th month of steroid treatment were as follows: FVC 80%, FEV₁ 64% and PEF 97%. Simultaneous thoracic HRCT revealed that bilateral peribronchial thickenings, atelectasic areas and bronchiectasic changes continued. The patient is currently being followed up with inhaled steroid treatment. Her clinical findings continue in the 5th year of the follow-up,

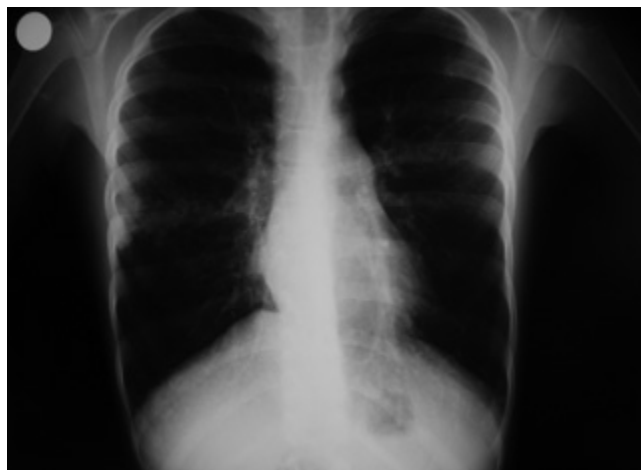

Figure 1. Interstitial appearance on lung graphy

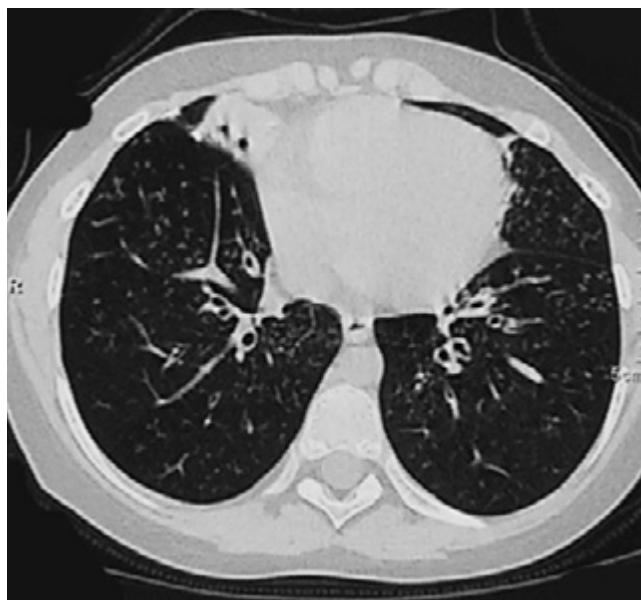


Figure 2. Bronchiectasis and atelectasis areas from place to place on thoracic high resolution computerized tomography

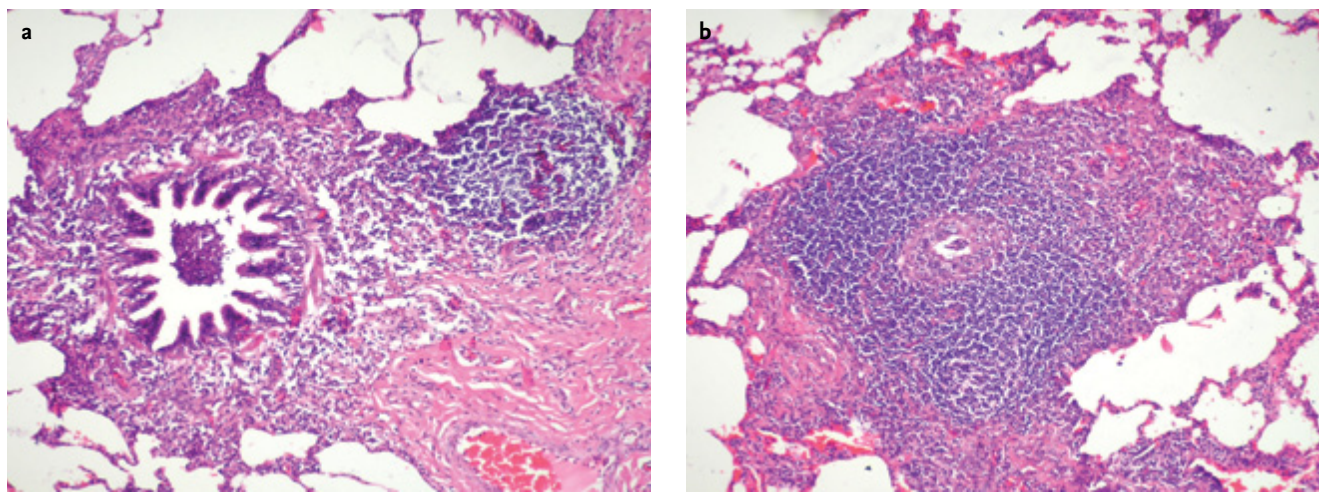


Figure 3a, b. Peribronchial lymphocyte infiltration and lymphoid follicular areas on biopsy samples

though they are decreased. No other morbidity which may be involved in the etiology developed. However, nasal obstruction and bilateral nasal polyposis which negatively affected the quality of life was found in the third year in the follow-up. Nasal polyposis required surgical resection, since it was resistant to topical and systemic steroid treatment. Consent was obtained from the mother of the patient for preparation of this case report.

Discussion

In this case report, an eight-year old patient who was diagnosed with primary FB on open lung biopsy which was performed because of continuing complaints and lung parenchymal findings despite treatment and who developed severe nasal polyposis in the follow-up was presented. The association of follicular bronchiolitis and nasal polyposis has not been reported before.

Follicular bronchiolitis which more frequently occurs in adults is frequently observed in patients who present with cough, progressive dyspnea and recurrent pneumonia (1, 2, 6). It frequently occurs secondary to conditions including connective tissue diseases, non-specific infections, immune deficiencies [especially acquired immune deficiency syndrome (AIDS)], common variable immune deficiency syndrome, IgA deficiency and hypersensitivity. Primary cases are observed especially rarely in the childhood (1, 4, 5). Our patient showed compatibility with classical FB, since she presented with chronic cough and had fine rales on auscultation. Viral markers and autoantibodies tested in terms of etiology were found to be negative and immunoglobulin levels and lymphocyte panel were found to be normal. In the

five-year follow-up period, no morbidity which might be involved in the etiology developed. Follicular bronchiolitis is considered hyperplasia of bronchial associated lymphoid tissue, pulmonary lymphoid hyperplasia. The lymphocytes increase as an immunological response to a regional antigen. However, follicular bronchiolitis does not always develop as a result of exposure to the same antigen. Therefore, antigenic stimulation theory is not sufficient in explaining the pathogenesis of FB. It is also thought that there is an immunological disorder leading to lymphocyte increase (7). It is composed of abundant peribronchial lymphoid follicles. They may be localized between the lymphoid follicular bronchioles and pulmonary arteries and compress the airway. In follicular bronchiolitis, secondary lesions including bronchiectasis, bronchiolectasis, bronchiolar fibrosis and organizing pneumonia frequently develop (2, 8).

In follicular bronchiolitis, pulmonary function tests may show obstructive, restrictive or mixed pattern or may be normal (2, 9). In a case presentation including two cases of follicular bronchiolitis, the respiratory function tests of the patients showed obstructive pattern (10). While the respiratory function tests of our patient was as follows at the first presentation: FEV₁ 59%, FVC 58% PEF 59% which were compatible with restrictive respiratory function test findings, the test findings at the sixth month of the follow-up were as follows: FEV₁ 64%, FVC 80% PEF 97%.

Thoracic high resolution computerized tomography findings show prominent bronchial opacities, peribronchial nodules, bronchiectasis and reduced lung aeration in FB (9, 11). In a study including 12 patients, peribronchial nodules were found in half of the patients and

bilateral centri-lobular infiltration was found in all patients. Ground-glass appearance was observed in 75% (2). In another case report of FB, peribronchial nodules with prominent centrilobular nodular distribution were also observed on thoracic HRCT in a 5-year old female patient (12). In our patients, peribronchial thickenings which were more prominent in bilateral lung bases, diffuse small nodules, bronchiectasis and bronchiolectasis were found at presentation which was compatible with these data.

Patients with follicular bronchiolitis typically have a good prognosis (2). In a publication in which two Turkish patients with FB were discussed, it was reported that the symptoms and thoracic HRCT findings of the patients regressed (10). However, tendency to progressive disease was found in the patients below the age of 30 years in one study (2). In addition, it was reported that the findings did not regress with systemic steroid treatment and immunosuppressive treatment was required in a case report of FB (13). Although there was regression in the findings in the follow-up of our patient, peribronchial thickenings which were more prominent in the bases of the lungs and bronchiectasis from place to place were found on thoracic HRCT after 6 months and this was considered progression.

Association of follicular bronchiolitis which is characterized with hyperplasia of the lymphoid tissue and nasal polyposis has not been reported before. In the follow-up of our patient, nasal polyposis which was resistant to topical and systemic steroid treatment developed and required surgery which was not a frequently expected finding. Allergen hypersensitivity, cystic fibrosis, primary ciliary dyskinesia and aspirin sensitivity which could be involved in the etiology of nasal polyposis were not found. Although this case report is not related with the pathogenesis of this association, reduction in Tregs and downregulation in the pathway of TGF-beta (transforming growth factor beta) are involved in occurrence of nasal polyposis (14). This may also play a role in lymphoid hyperplasia in FB and may be effective in explaining the association of these two conditions.

Conclusively, primary follicular bronchiolitis should be considered in patients who have continuing cough and dyspnea, whose parenchymal findings do not regress on lung auscultation and whose imaging suggests presence of reticulo-nodular lesions in the lung despite treatment. Though not reported before, these patients

should be followed up in terms of development of nasal polyposis considering the findings of our patient.

Informed Consent: Written informed consent was obtained from patients' parents.

Peer-review: Externally peer-reviewed.

Author Contributions: Concept - H.Y.; Supervision - H.Y.; Data Collection and/or Processing - E.T.K., A.T., Ş.Ş.; Writer - E.T.K., Ö.Y.

Conflict of Interest: No conflict of interest was declared by the authors.

Financial Disclosure: The authors declared that this study has received no financial support.

References

1. Travis WD, Galvin JR. Nonneoplastic pulmonary lymphoid lesions. *Torax* 2001; 56: 964-71.
2. Yousem SA, Colby TV, Carrington CB. Follicular bronchitis/bronchiolitis. *Hum Pathol* 1985; 16: 700-6. [\[CrossRef\]](#)
3. Howling SJ, Hansell DM, Wells AU, et al. Follicular bronchiolitis: thin-section CT and histologic finding. *Radiology* 1999; 212: 637-42. [\[CrossRef\]](#)
4. Kinane BT, Mansell AL, Zwerdling RG, Lapey A, Shannon DC. Follicular bronchitis in the pediatric population. *Chest* 1993; 104: 1183-6. [\[CrossRef\]](#)
5. Nicholson AG, Kim H, Corrin B, et al. The value of classifying interstitial pneumonitis in childhood according to defined histological patterns. *Histopathology* 1998; 33: 203-11. [\[CrossRef\]](#)
6. Nicholson AG, Wotherspoon AC, Diss TC, et al. Reactive pulmonary lymphoid disorders. *Histopathology* 1995; 26: 405-12. [\[CrossRef\]](#)
7. Kradin RL, Mark EJ. Benign lymphoid disorders of the lung, with a theory regarding their development. *Hum Pathol* 1983; 14: 857-67. [\[CrossRef\]](#)
8. Kinane BT, Mansell AL, Zwerdling RG, Lapey A, Shannon DC. Follicular bronchitis in the pediatric population. *Chest* 1993; 104: 1183-6. [\[CrossRef\]](#)
9. Reitter P, Fötter R, Lindbichler F, et al. HRCT features in a 5-years-old child with follicular bronchiolitis. *Pediatr Radiol* 1997; 27: 877-9. [\[CrossRef\]](#)
10. Benesh M, Kurz H, Eber E, et al. Clinical and histopathological findings in two Turkish children with follicular bronchiolitis. *Eur J Pediatr* 2001; 160: 223-6. [\[CrossRef\]](#)
11. Wells AU. Computed tomographic imaging of bronchiolar disorders. *Curr Opin Pulm Med* 1998; 4: 85-92. [\[CrossRef\]](#)
12. Dai Y, Lin L, Tang H, Jiang K. Follicular bronchiolitis in a child. *World J Pediatr* 2011; 7: 176-8. [\[CrossRef\]](#)
13. Reitter P, Fötter R, Lindbichler F, et al. HRCT features in a 5-years old child with follicular bronchiolitis. *Pediatr Radiol* 1997; 27: 877-9. [\[CrossRef\]](#)
14. Van Crombruggen K, Zhang N, Gevaert P, Tomassen P, Bachert C. Pathogenesis of chronic rhinosinusitis: inflammation. *J Allergy Clin Immunol* 2011; 128: 728-32. [\[CrossRef\]](#)