

# Diagnosis of Congenital Cytomegalovirus in a 14-Month-Old Patient Presenting with Sensorineural Hearing Loss: Storing Dry Blood Samples

Anil Gök<sup>1</sup>, Gökçe Cirdi<sup>1</sup>, Ayfer Sakarya Güneş<sup>1</sup>, Leman Tekin Orgun<sup>1</sup>, Murat Sayan<sup>2</sup>, Bülent Kara<sup>1</sup>

<sup>1</sup>Division of Child Neurology, Department of Pediatrics, Kocaeli University School of Medicine, Kocaeli, Türkiye

<sup>2</sup>Clinical Laboratory-PCR Unit, Kocaeli University School of Medicine, Kocaeli, Türkiye

Congenital cytomegalovirus (CMV) infection is a significant public health concern and leading cause of sensorineural hearing loss (SNHL) in children. While some infants with congenital CMV infection present with symptoms at birth, others may be asymptomatic, yet still at risk of developing hearing loss later in life.<sup>1</sup> Despite the considerable clinical implications of congenital CMV infection, it frequently remains undetected because the vast majority of infected infants are asymptomatic at birth. Screening programs have not been widely established.<sup>2</sup> Confirmation of congenital CMV infection must be performed before the 21st day of life through polymerase chain reaction (PCR) testing of saliva or urine samples. Given that neurosensory sequelae may arise delayed, neurological and auditory follow-up should extend well beyond the neonatal period.<sup>3</sup>

We report the case of a 14-month-old male patient who was referred from the ear, nose, and throat clinic to the child neurology clinic due to bilateral SNHL with the consent of his parents. He was born at 38+2 gestational weeks to healthy and unrelated parents, with a birth weight of 2360 g and a head circumference of 34 cm. The patient did not pass the otoacoustic emission test on either side on postnatal days 3, 7, and 15. Auditory brainstem response (ABR) testing was performed at 40 and 60 days of age, which resulted in failure in both ears. Consequently, the patient was provided with a hearing aid. At the patient's first presentation to the pediatric neurology outpatient clinic, weight was 10 kg (-0.68 SDS (Standard Deviation Score), height was 75 cm (-1.53 SDS), and head circumference was 44.5 cm (-2.22 SDS). According to an assessment of his neuromotor development, he was found to be age-appropriate with the exception of his speech. Despite the use of a hearing aid, the patient did not demonstrate any response to sounds. No atypical facial features or dysmorphic findings were noted. Cranial tomography was performed to assess intrauterine infection, and no intracalcification was detected (Figure 1A). Additionally, basic metabolic tests were performed by our team to evaluate congenital metabolic disorders, and the results were interpreted as normal. Based on these results, cranial magnetic resonance imaging (MRI) was performed. Cranial MRI revealed mild enlargement of the left ventricle, T2 hyperintense and T1 hypointense signal changes around the posterior horns of the ventricles (Figure 1B and C). Cranial MRI demonstrated characteristics consistent with congenital CMV infection. To confirm the presence of congenital CMV infection, a request was made to the Provincial Health Directorate for dried blood samples (Guthrie cards) collected from the patient's heels during the neonatal period. Analysis of the dry blood samples revealed a CMV load of 1.330 IU/mL, which was deemed positive for congenital CMV infection. The patient was referred to the ear, nose, and throat outpatient clinic for cochlear implantation.

Although several factors contribute to congenital hearing loss in newborns and children, genetic and environmental factors are the most important. Ongoing genetic research has revealed that 80% of congenital hearing loss cases in developed countries are due to genetic factors, while the remaining 20% are attributed to environmental or acquired

## Corresponding author:

Anil Gök

✉ anil.gok@kocaeli.edu.tr

Received: August 27, 2024

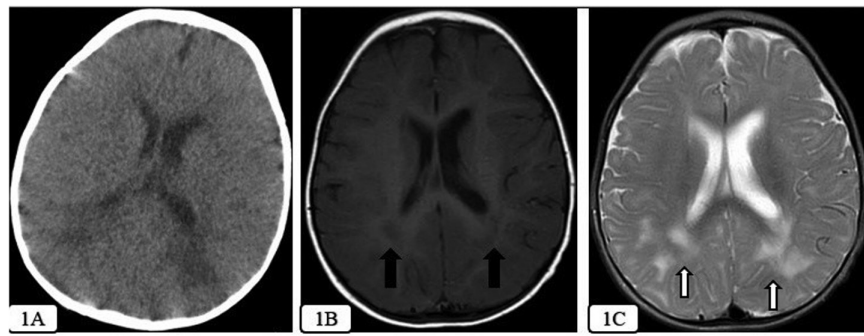
Accepted: October 12, 2024

Publication Date: January 2, 2025

Content of this journal is licensed under a Creative Commons Attribution-NonCommercial 4.0 International License.



**Cite this article as:** Anil G, Gökçe C, Ayfer SG, Leman TO, Murat S, Bülent K. Diagnosis of congenital CMV in a 14-month-old patient presenting with sensorineural hearing loss: storing dry blood samples. *Turk Arch Pediatr.* 2025;60(1):106-107.



**Figure 1.** (A) No intracalcification was detected on cranial CT. (B) Hypointense signal changes around the posterior horns of the ventricles on T1 cranial MRI are showed by the black arrows. (C) Hyperintense signal changes around the posterior horns of the ventricles on T2 cranial MRI are showed by the white arrows.

causes. Environmental factors that contribute to the onset of congenital hearing loss include prenatal TORCH infections, such as toxoplasmosis, syphilis, rubella, cytomegalovirus, and herpes, and postnatal bacterial meningitis. In developing countries, congenital CMV infection is increasingly recognized as the primary environmental cause of congenital hearing loss.<sup>4</sup> Periventricular calcification may not be consistently detected through computed tomography scans in cases of suspected congenital CMV. While ventriculomegaly and non-homogeneous signal changes in the white matter are the most frequently reported non-specific abnormalities on MRI, more distinct yet less commonly observed findings include temporal lobe lesions characterized by abnormal white matter, cysts, enlarged temporal horns, ventriculitis, and intracranial calcification.<sup>5</sup>

Magnetic resonance imaging findings in our case showed mild dilatation of the left ventricle and the presence of non-homogeneous white matter changes in the posterior horns of the ventricles, which were hyperintense on T2-weighted images and hypointense on T1-weighted images (Figure 1B and C).

To diagnose congenital CMV, CMV PCR should be performed using urine or saliva samples obtained during the first 21 days of life. It is challenging to determine the presence of prenatal or postnatal infections in the samples collected after this period. It is also advisable to obtain saliva samples prior to breastfeeding if possible. Given that most newborns are asymptomatic at birth, diagnosing congenital CMV becomes even more difficult after the postnatal 21st day.<sup>3,6</sup> Saliva samples may also have a high false-positive rate.<sup>7</sup> In such cases, CMV PCR can be performed on dry blood samples obtained during the neonatal period. This is because these were the only blood samples stored in the first 21 days of the patient.<sup>8-10</sup>

It is a requirement in our nation that dry blood samples, also known as Guthrie cards, which are collected for screening purposes, be retained for a period of five years. When congenital CMV is suspected and the patient has missed the initial 21-day interval, Guthrie cards can be requested from the provincial health directorate, and CMV PCR testing can be conducted.

In summary, it is essential to recognize that the performance of CMV PCR on dried blood samples is an option for definitive diagnosis in cases of suspected congenital CMV when the initial 3-week period has been missed.

**Availability of Data and Materials:** The data that support the findings of this study are available on request from the corresponding author.

**Informed Consent:** Verbal informed consent was obtained from the patient's legal guardians who agreed to take part in the study.

**Peer-review:** Externally peer-reviewed.

**Author Contributions:** Concept – A.G., B.K.; Design – A.G., B.K.; Supervision – L.T.O., B.K.; Resources – A.G., G.C., A.S.G.; Materials – A.G., G.C., A.S.G., L.T.O.; Data Collection and/or Processing – A.G., G.C., A.S.G., L.T.O.; Analysis and/or Interpretation – M.S.; Literature Search – A.G., G.C., A.S.G.; Writing – A.G.; Critical Review – B.K.

**Declaration of Interests:** The authors have no conflicts of interest to declare.

**Funding:** This study received no funding.

## REFERENCES

1. Fowler KB, Boppana SB. Congenital cytomegalovirus (CMV) infection and hearing deficit. *J Clin Virol.* 2006;35(2):226-231. [\[CrossRef\]](#)
2. Marsico C, Kimberlin DW. Congenital Cytomegalovirus infection: advances and challenges in diagnosis, prevention and treatment. *Ital J Pediatr.* 2017;43(1):38. [\[CrossRef\]](#)
3. Nicloux M, Peterman L, Parodi M, Magny JF. Outcome and management of newborns with congenital cytomegalovirus infection. *Arch Pediatr.* 2020;27(3):160-165. [\[CrossRef\]](#)
4. Choe G, Park SK, Kim BJ. Hearing loss in neonates and infants. *Clin Exp Pediatr.* 2023;66(9):369-376. [\[CrossRef\]](#)
5. Diogo MC, Glatter S, Binder J, Kiss H, Prayer D. The MRI spectrum of congenital cytomegalovirus infection. *Prenat Diagn.* 2020;40(1):110-124. [\[CrossRef\]](#)
6. Kabani N, Ross SA. Congenital cytomegalovirus infection. *J Infect Dis.* 2020;221(suppl 1):S9-S14. [\[CrossRef\]](#)
7. Günlemez A, Kolaylı F, Yazıcı Özçelik E, et al. Congenital cytomegalovirus infection screening in newborns from saliva samples by real-time polymerase chain reaction analysis. *Turk Arch Pediatr.* 2023;58(4):371-375. [\[CrossRef\]](#)
8. Almeida S, Gouveia P, Jorge A, et al. Diagnosing congenital cytomegalovirus infections using archived dried blood spots: A 15-year observational study, Portugal. *J Clin Virol.* 2023;165:105516. [\[CrossRef\]](#)
9. Pellegrinelli L, Alberti L, Pariani E, Barbi M, Binda S. Diagnosing congenital Cytomegalovirus infection: don't get rid of dried blood spots. *BMC Infect Dis.* 2020;20(1):217. [\[CrossRef\]](#)
10. Boudewyns A, Declau F, Smets K, et al. Cytomegalovirus DNA detection in Guthrie cards: role in the diagnostic work-up of childhood hearing loss. *Otol Neurotol.* 2009;30(7):943-949. [\[CrossRef\]](#)